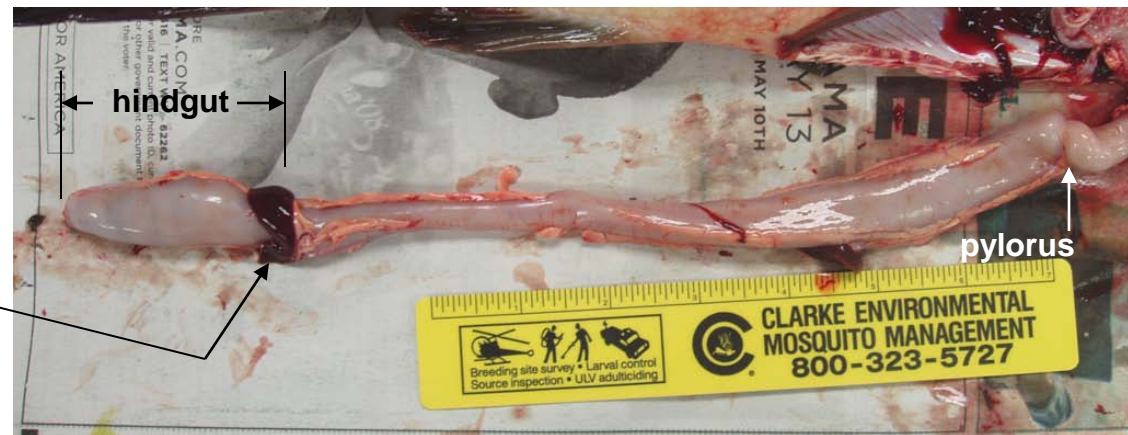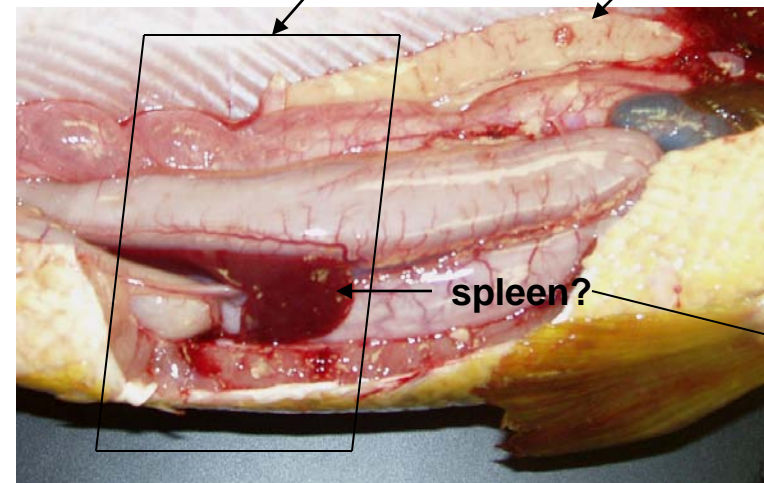
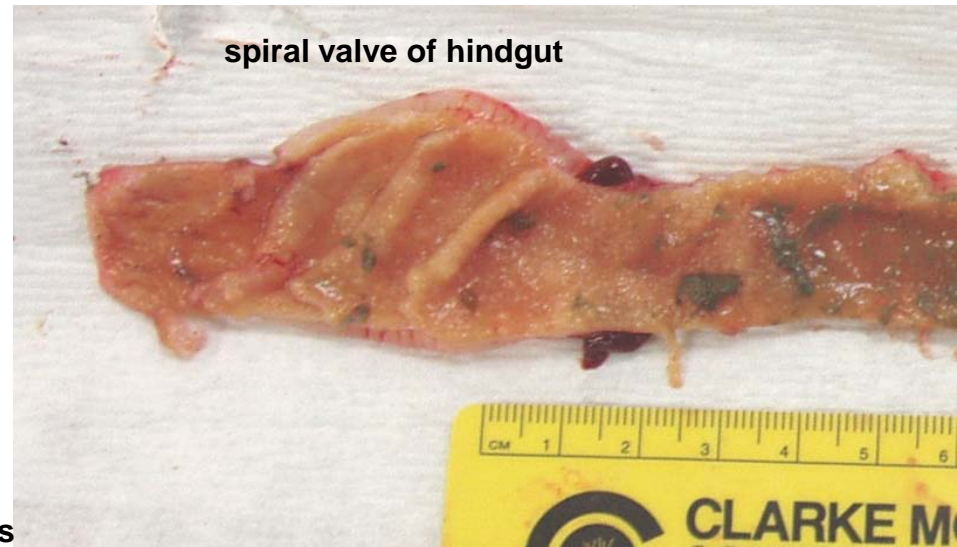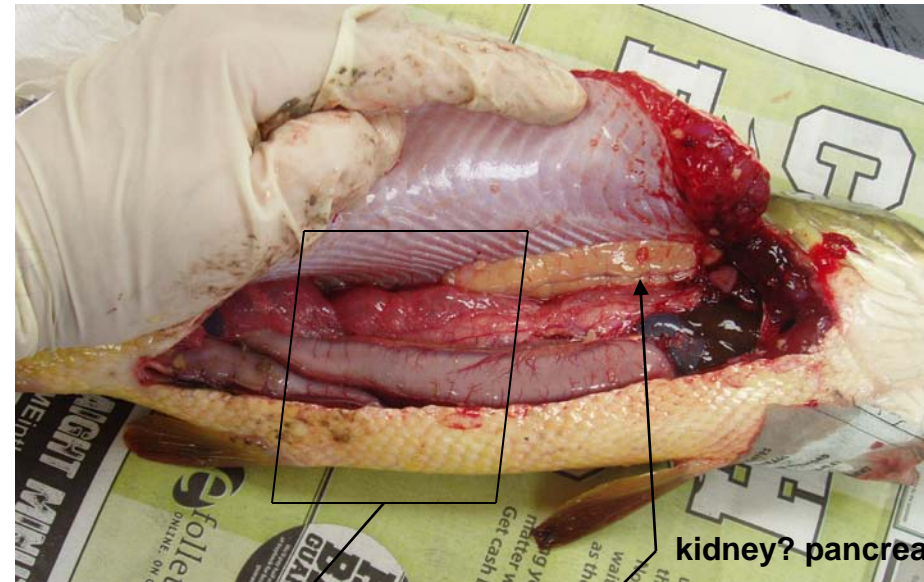
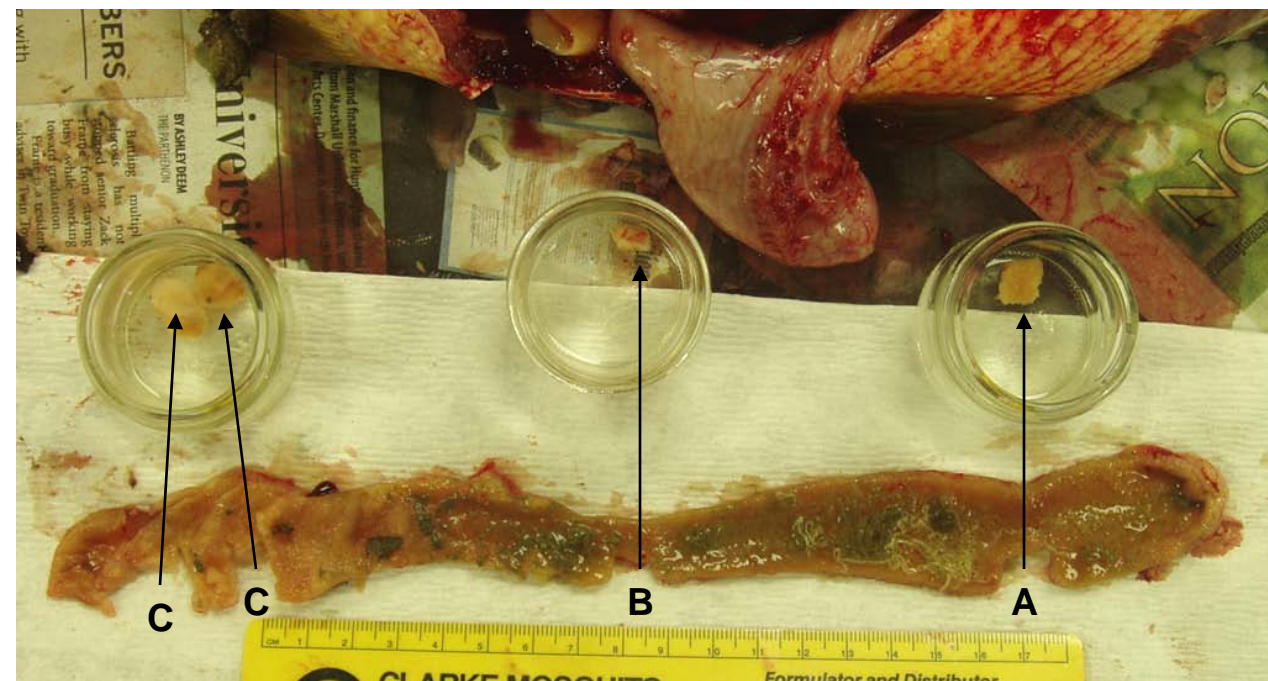


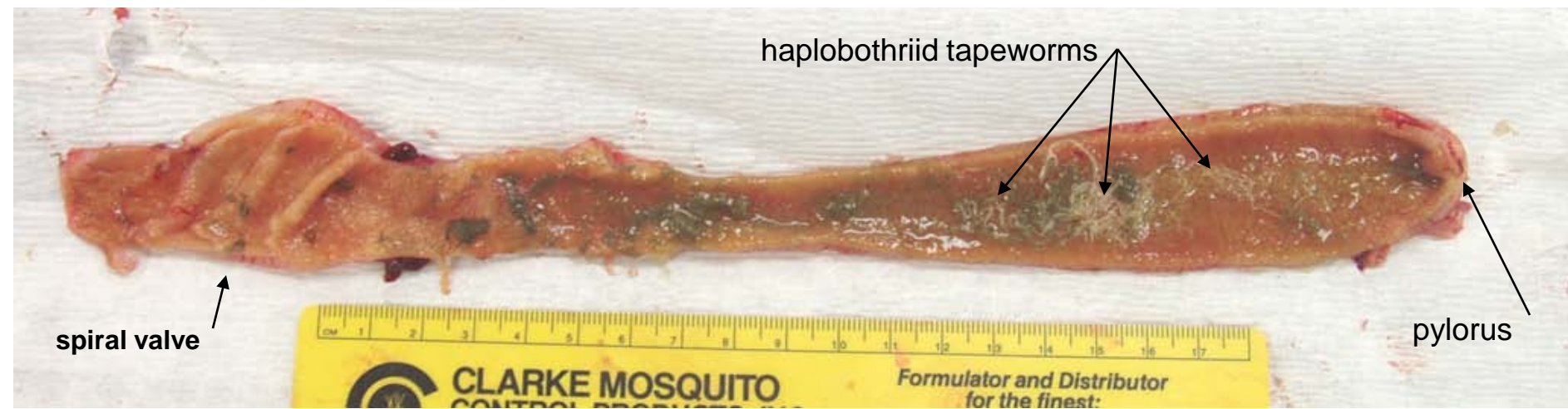*Amia calva* viscera.





*Amia calva* #23  
intestine. A = proximal  
midgut; B = “mid”  
midgut; C = hindgut  
(spiral valve) blocks for  
tissue sectioning.